

Image Case: Extraction of an Impacted Coin in Upper Esophagus in 3 Years Old Female

Mohamed I Radwan, Mohamed H Emara

Tropical Medicine Department, Faculty of Medicine, Zagazig University, Egypt

Corresponding author:
Mohamed I Radwan
email:
mradwan@zu.edu.eg

*mobile:*002010688872
85

*Received :*11 /6/2012

Accepted after

revision: 30/6 /2012

A 3-year-old female swallowed a large metallic coin (one Egyptian pound; the largest coin in Egypt). Laryngeal examination failed to demonstrate the coin and serial X ray films showed the

coin impacted in the upper esophagus. Extraction under general anesthesia was done 5 days after swallowing. Areas of pressure necrosis at the site of impaction, as well as changes in the coin were noticed.

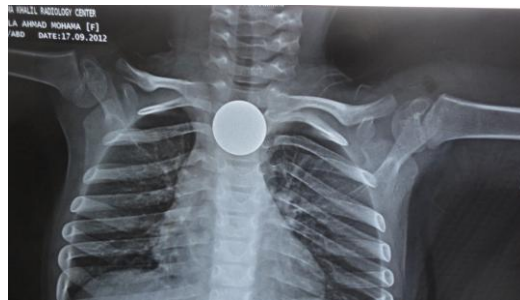


Figure (1): X ray showing the coin impacted in upper esophagus.



Figure (2): The extracted coin.